

Ophthalmology

CLASS procedure offers alternative treatment for glaucoma

Using a CO₂ laser may be suitable for patients with uncontrolled glaucoma in whom a less invasive approach is preferred.

Ocular Surgery News U.S. Edition, July 25, 2014
Shlomo Melamed, MD

Glaucoma can be an unpredictable disease that responds differently to treatment options from patient to patient. Despite having several treatment and surgical options available, none of these are effective in 100% of glaucoma cases.

Treatment for glaucoma usually begins with topical medications proven effective at lowering IOP when used as directed. However, the efficacy of these medications is limited due to a significant number of patients who are not fully compliant with the treatment regimen. We attribute this to a variety of reasons, including the high cost of the medication and the difficulty and frequency of properly instilling ocular drops. Traditional surgical solutions, such as trabeculectomy and tube shunts, require penetration into the globe and embedding a foreign object in the eye. These procedures may be associated with complications such as uncontrolled filtration, hypotony, choroidal detachment, leaking blebs, blebitis, endophthalmitis, foreign body sensation and dellen formation.

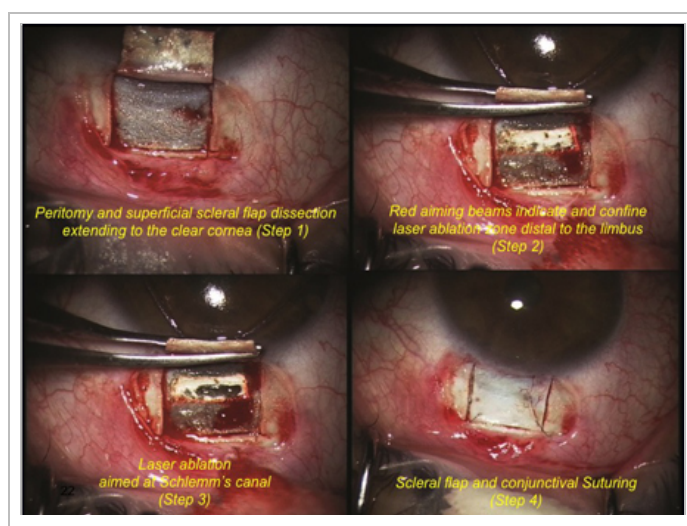
With a goal to increase the long-term success rate and improve safety, we began looking into an alternative, less invasive and simpler method to treat glaucoma patients. Carbon dioxide laser sclerectomy surgery (CLASS) is proving to be a good option.

The CLASS procedure is performed on the IOPtiMate (IOPtima) system, which consists of a 10.6 μm wavelength CO₂ laser accompanied by a micro-manipulating scanner and a control unit. By thinning the sclera of the eye, the IOP-causing fluid percolates through Schlemm's canal, with the trabecular meshwork left intact after ablation of the "roof" by the CO₂ laser. The anterior chamber is not penetrated, and there is no need to insert and leave a foreign object in the eye. Patients with mild to moderate primary open-angle glaucoma and pseudoexfoliation glaucoma benefit the most from CLASS.

The technique

The CLASS procedure is simple and elegant. To begin, create a conjunctiva flap to expose the limbus using the fornix base method and a standard scleral flap 5 mm × 5 mm into the clear cornea. Then there is the option to create a scleral bed as a fluid reservoir. The CO₂ laser beam is guided by the micro-manipulating beam to ablate thin layers of dry sclera in a pre-selected pattern to "un-roof" Schlemm's canal, allowing aqueous to percolate through the intact trabecular meshwork. The laser energy is absorbed by the percolating fluid, terminating the ablation. To conclude, close and suture the scleral flap and conjunctiva.

In addition to not penetrating the anterior chamber, one of the greatest benefits of CLASS is the ease of performing the procedure. The technique for unroofing the canal is safe and productive. IOP is significantly reduced with less risk of hypotony, and the impact on vision is minimal. CLASS may be most suitable for patients with uncontrolled glaucoma in whom a less invasive approach is preferred.



Step 1: Peritomy and superficial scleral flap dissection extends to the clear cornea. Step 2: Red aiming beams indicate and confine laser ablation zone distal to the limbus. Step 3: Laser ablation is aimed at Schlemm's canal. Step 4: Scleral flap and conjunctiva are sutured.

Image: Melamed S

Clinical results

A prospective, multicenter study was conducted at nine global sites, including ones located in Central America, Western and Eastern Europe, Mediterranean countries and Asia, with a variety of demographics. The study included 111 patients; the procedure was performed on 85 eyes with primary open-angle glaucoma and 26 eyes with pseudoexfoliation glaucoma with an average IOP of 25.7 ± 5.3 mm Hg. Mean IOP dropped to 13.5 ± 3.7 mm Hg at 6 months postoperative in 86 eyes and remained stable through 3 years in 29 eyes and 5 years in eight eyes. The average number of hypotensive medications dropped from a mean of 2.3 ± 1.2 at baseline to 0.3 ± 0.7 at 6 months postoperative, 0.6 ± 0.8 after 3 years and 0.78 ± 1.0 after 5 years. At 3 years postoperative, 87.5% of patients achieved a reduction in IOP of 20% or greater, maintaining an IOP of 18 mm Hg or less; 59.4% of patients were able to maintain the IOP goals without use of any medication. Mitomycin C was used in 93% of procedures.

Conclusion

On a global level, glaucoma is the second leading cause of blindness. An estimated 8.4 million people in the world have glaucoma-induced blindness and an additional 60 million are affected by optic neuropathy. The CLASS procedure allows us to treat patients earlier in the disease process, and it is a simple, highly successful technique. With promising data collected on more than 700 procedures performed worldwide, I am confident that it works well, providing significant, long-term reduction in both IOP and hypotensive medication requirements, with a low rate of postoperative complications. Future studies will hopefully continue to demonstrate the benefits of using CO₂ lasers in treating glaucoma.

References:

Cook C, et al. *Can J Ophthalmol*. 2012;doi:10.1016/j.jcjo.2012.02.003.

Friedman DS, et al. *Invest Ophthalmol Vis Sci*. 2007;doi:10.1167/iovs.07-0290.

Kass MA, et al. *Arch Ophthalmol*. 2002;doi:10.1001/archophth.120.6.701.

For more information:

Shlomo Melamed, MD, can be reached at melamed.choka88@gmail.com.

Disclosure: Melamed receives research grants from Allergan, Solx, Ellex, IOPTima and Eyetechnicare.

Healio.com Ophthalmology Videos

Subluxated bag-IOL
complex with

SIGS with Glued
Capsular Hook with

Soosan Jacob
introduces her new

MORE »